

# ULTRA-WIDE FIELD Fluorescein Angiography in SICKLE CELL RETINOPATHY: Correlations Between Peripheral Non-perfusion Area and Macular Vascular Density on Optical Coherence Tomography Angiography.

Poster

N° 5425 – A0094

ARVO Annual Meeting  
April 29-May 3, 2018  
Honolulu, Hawaii

*Kamami-Levy, Cynthia MD. MSc<sup>1</sup>; Debillon, Pierre MD<sup>1</sup>; Mouallem Alexandra MD<sup>1</sup>; Bruyere, Elsa MD<sup>1</sup>; Miere Alexandra MD<sup>1</sup>; Amoroso, Francesca MD<sup>1</sup>; Jung Camille MD<sup>1</sup>; Souied, Eric H. MD. PhD<sup>1</sup>.*

1. Ophthalmology department – Retina Unit, Centre Hospitalier Intercommunal de Creteil, University Paris Est Creteil, Créteil, France.



## Purpose

In patients with sickle cell retinopathy (SCR), to study correlations between peripheral retinal nonperfusion assessed using ultra-wide field fluorescein angiography (UWF-FA) and the automatically quantified macular vascular densities in the superficial (SCP) and deep capillary plexus (DCP) obtained using optical coherence tomography angiography (OCTA).

## Methods

Prospective, observational study of patients with sickle cell retinopathy who underwent a comprehensive ophthalmic examination including UWF-FA (Optos, Marlborough, MA) and OCTA using the AngioVue OCTA system (Optovue RTVue XR 100; AVANTI, Fremont, CA) and PlexElite (Zeiss). Vascular densities in the superficial capillary plexus and DCP, as well as the area of the foveal avascular zone, were measured using AngioAnalytics software. Ischemic areas were manually selected and the ischemic index was automatically calculated in mm<sup>2</sup> with the Optos Advance software using a correction factor in the peripheral retina.

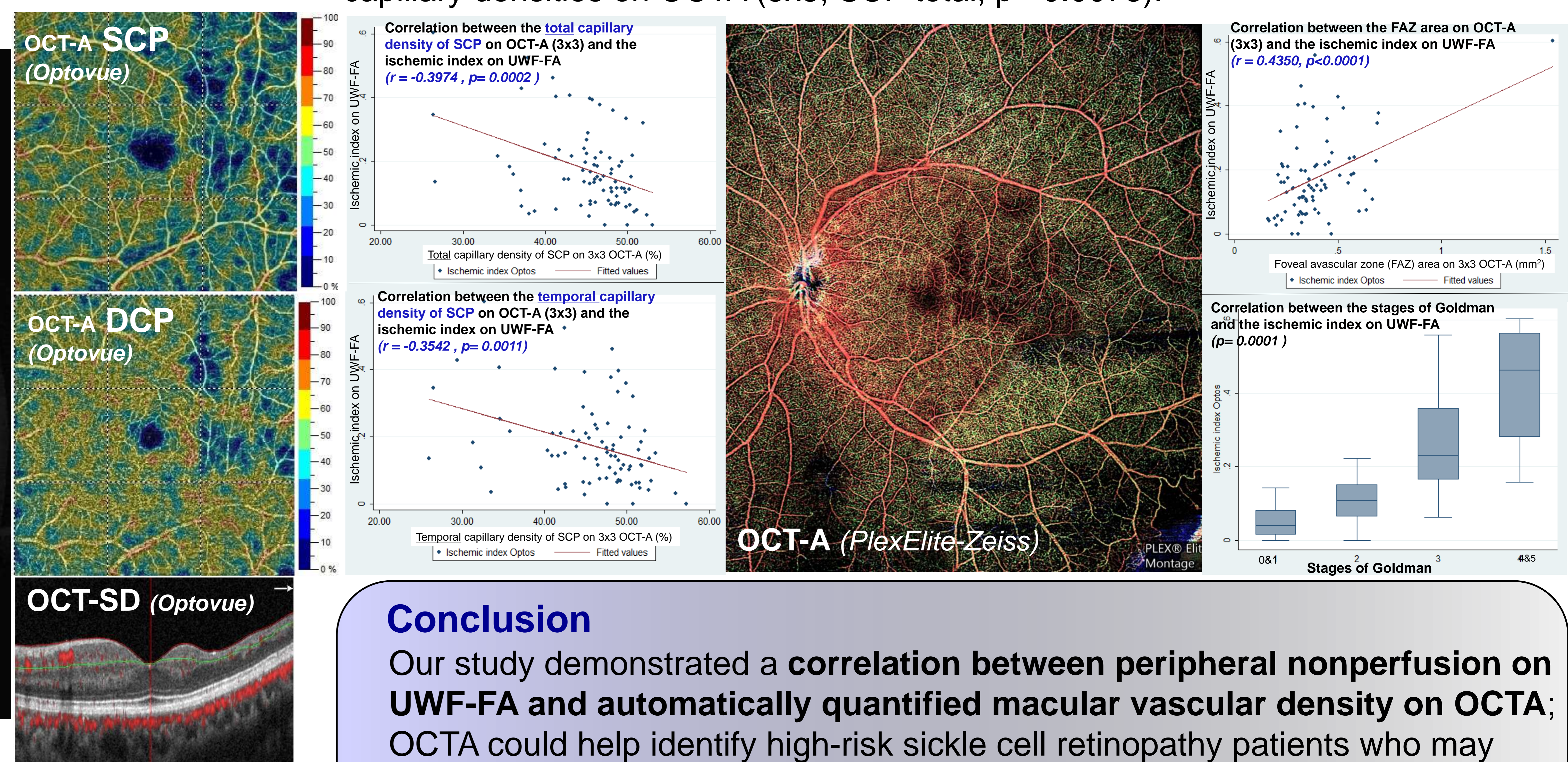
## Results

Eighty-four eyes from 42 consecutive patients (22 men, 20 women) with SCR were included between June 2017 and March 2018. Mean age was 32.3 years (min 14; max 68). Twenty-one patients (42 eyes) were SS, 19 patients (38 eyes) were SC and 2 patients were SB0. Twenty-four eyes (29%) were previously treated with laser. Mean BCVA was 0,1 LogMAR (min 3; max -0.1).

The **ischemic index** measured in the peripheral retina on UWF-FA was correlated with the measured **FAZ** on OCTA (Person,  $r = 0.4350$ ,  $p < 0.0001$ ), and with the **capillary densities** of the **total SCP** (Person,  $r = -0.3974$ ,  $p = 0.0002$ ) and of the parafoveal **temporal SCP** ( $r = -0.3542$ ,  $p = 0.0011$ ) on OCTA 3x3.

The **ischemic index** was also correlated with the **capillary densities** of the **total DCP** ( $r = -0.3344$ ,  $p = 0.0021$ ) and of the **temporal DCP** ( $r = -0.3297$ ,  $p = 0.0025$ ) on OCTA 3x3.

The ischemic index was also correlated with the capillary densities on OCTA 6x6. The stages of Goldman were correlated with the ischemic index ( $p = 0.0001$ ) and with the capillary densities on OCTA (3x3, SCP total,  $p = 0.0073$ ).



## Conclusion

Our study demonstrated a **correlation between peripheral nonperfusion on UWF-FA and automatically quantified macular vascular density on OCTA**; OCTA could help identify high-risk sickle cell retinopathy patients who may benefit from further evaluation using UWF-FA. UWF-FA allowed a more precise topographic analysis of vascular abnormalities and ischemia areas than with conventional fluorescein angiography.

## References

1. **Macular microangiopathy in sickle cell disease using optical coherence tomography angiography**, Minvielle W, Caillaux V, Cohen SY, Chasset F, Zambrowski O, Miere A, Souied EH. Am J Ophthalmol. 2016 Apr;164:137-44.e1.
2. **Correlation of multimodal imaging in sickle cell retinopathy**, Ghasemi Falavarjani K, Scott AW, Wang K, Han IC, Chen X, Klufas M, Hubschman JP, Schwartz SD, Sadda SR, Sarraf D, Tsui I. Retina 2016 Dec;36 Suppl 1:S111-S117.